

Localization of NMDAR-related epitopes in ovarian teratoma: comparison between patients and controls

Naoko Tachibana, M.D.¹⁾ and Shu-ichi Ikeda, M.D.²⁾

Abstract: To clarify the role of ovarian teratomas in the pathogenesis of anti-N-methyl-D-aspartate receptor (NMDAR) encephalitis, we examined histopathologically ovarian teratomas with and without encephalitis as well as normal ovaries. We found strong expression of N-methyl-D-aspartate receptor subtype 2B (NR2B) epitopes in the cytoplasm of oocytes obtained from human and bovine ovaries. A substantial amount of neural tissues expressing NR2B immunoreactivity chiefly in the mature neurons was observed. However, between both groups of ovarian teratomas, no significant difference in either the amount of neural tissues or the degree of inflammatory cell infiltration was observed.

Young females comprise around 80% of all anti-NMDAR encephalitis patients, and it has been reported that 39% of them have ovarian teratomas. It is also well known that the vast majority of encephalitis patients have prodromal infection before onset of the disease. If this infection affects either normal ovaries or ovarian teratomas, it may trigger the expression of NMDAR-related epitopes in oocytes. Therefore, ovarian teratomas that consist of large amounts of neural tissue might indicate an increased risk for development of this type of intractable encephalitis.

(臨床神経 2012;52:982-984)

Key words : anti-NMDAR encephalitis, NMDAR-related epitopes, ovarian teratoma, oocyte, prodromal infection

Introduction

Anti-N-methyl-D-aspartate receptor (NMDAR) encephalitis is a recently established disorder that predominantly affects women of reproductive age with ovarian teratomas. Therefore, it is considered to be a type of paraneoplastic encephalitis¹⁾. However, based on accumulated information from a rapidly increasing number of patients, only about 39% of women have ovarian teratomas^{2,3)}. Therefore, the factors that promote the production of anti-NMDAR antibodies remain unclear. Another important clinical feature of the disease is the presence of preceding infectious episodes, which was demonstrated in 70-90% of patients. We hypothesized that these infectious episodes may lead to inflammation in the ovaries and promote onset of the disease. To examine this hypothesis, we performed immunohistochemical studies of ovarian teratomas removed from both patients with anti-NMDAR encephalitis and control patients, paying special attention to the amount of neural tissues, anti-NMDAR-related epitopes and severity of inflammatory cell infiltration. Similar

examinations were also performed for normal ovaries. The immunohistochemical staining methods were described previously⁴⁾.

NMDAR-related epitopes in normal ovary

About 80% of anti-NMDAR encephalitis patients are women of reproductive age. Why does this disease mainly develop in younger females? We initially thought that ovaries themselves might contain NMDAR-epitopes⁴⁾. To answer this question, we investigated five ovaries obtained from young females at autopsy. NR2B immunoreactivity was commonly seen in the cytoplasm of oocytes in all five cases. If NMDAR-related epitopes in normal oocytes are able to induce an antigen-antibody reaction, the presence of NR2B immunoreactivity in oocytes offers a possible explanation for the selective involvement of young females with this disease.

¹⁾Department of Neurology, Okaya City Hospital [Okaya, Japan]

²⁾Department of Medicine (Neurology & Rheumatology), Shinshu University School of Medicine [Matsumoto, Japan]

(Received: 23 May 2012)

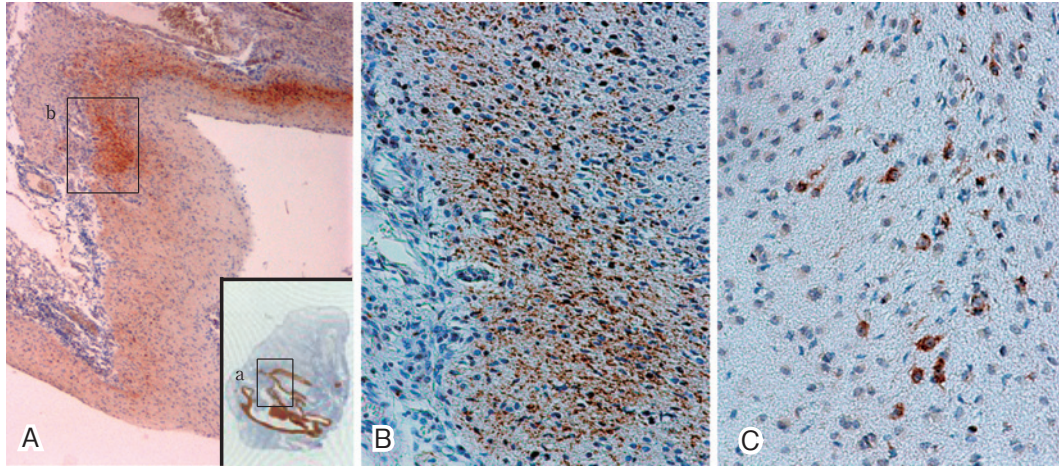


Fig. 1 Expression of neural antigens in an ovarian teratoma removed from a patient with anti-NMDAR encephalitis.

A: GFAP- and SMI-31 (antibody for neurofilament)-immunoreactive areas. The picture is an enlargement of the framed area in the insert. SMI-31-immunoreactive area is seen. The insert shows the GFAP-immunoreactive area in an ovarian teratoma. Immunoperoxidase staining $\times 32$, insert $\times 1.3$. B: An enlargement of the framed area b in figure A. SMI-31-immunoreactive fibrous structures are more clearly seen. Immunoperoxidase staining $\times 150$. C: a significant number of small neurons with NR2B-immunoreactivity are visible. Immunoperoxidase staining $\times 180$.

Neural tissues and NMDAR epitopes in ovarian teratoma

Anti-NMDAR encephalitis was first reported in 2007 as paraneoplastic encephalitis. In this report, all 12 patients were females and all of them had ovarian teratoma¹⁾. Based on the fact that ovarian teratomas contain CNS-like tissues, it was accepted that ovarian teratomas played an initial role in the pathogenesis of this type of encephalitis⁵⁾.

To clarify the role of ovarian teratomas in the onset of this disease, we investigated numerous ovarian teratomas using serial sections prepared from formalin-fixed and paraffin-embedded blocks. The capsular layers in cystic tumors contain squamous epithelium, exocrine and sebaceous gland, hair follicles, fat, and neural tissues. These neural tissues were positively stained with an anti-glial fibrillary acidic protein (GFAP) antibody (Fig. 1-A). In the same area synaptophysin-immunoreactive or microtubule-associated protein-2 (MAP-2)-immunoreactive tissues were observed (Fig. 1-B), as well as NR2B-immunoreactive neurons (Fig. 1-C) and/or GluR2/3 positive neurons. These findings suggest that ovarian teratomas with neural tissues are stimulated by some unknown factors that promote the appearance of NMDAR antigens and subsequent production of anti-NMDAR antibodies.

Neural components and inflammatory cell infiltration in ovarian teratoma

Although a recent study demonstrated that only 39% of the female patients with anti-NMDAR encephalitis have ovarian teratomas, ovarian teratoma still appears to be the chief predisposing factor for this disease. Therefore, we wanted to know whether neural tissues in ovarian teratomas with encephalitis are different from those without encephalitis. To answer this question, we performed computer-assisted morphometry to compare the presence of neural tissues in ovarian teratomas obtained from both encephalitis and control patients. The neural tissues in ovarian teratomas were identified as GFAP-immunoreactive areas. No difference in the amount of neural tissues was observed between both groups. We then examined the degree of inflammatory cell infiltration and the expression of lymphocyte surface antigens. Inflammatory cell infiltration was frequently seen in both groups of ovarian teratomas, but the difference was not significant. Additionally, no specific tendency of lymphocyte subtype surface antigens was seen in these tumors. These results further suggest that the pathogenesis of anti-NMDAR encephalitis cannot be explained by the theory of paraneoplastic neurogenic disorder.

The pathogenesis of anti-NMDAR encephalitis

Ovarian teratomas originate in oocytes and are one of the types of benign tumors that frequently occur in young females. In ovaries most ovarian follicles develop from the primordial follicles into Graaf follicles. Furthermore, concomitant inflammation is likely to occur during menses. Ovulation alone causes a varying degree of inflammation, and ovaries accompanied by bacterial and/or viral infections have an even greater chance of becoming inflamed. Due to the relatively small size of the ovaries, ovarian teratomas are almost certainly more easily affected by such inflammation.

An infection reported in 70-90% of patients in previous studies¹⁾²⁾ might be the most important factor related to the initial role of anti-NMDAR antibody production. If the preceding infection is present in either normal ovaries or ovarian teratomas, tissues are destroyed and inherent NMDAR-related antigens are possibly exposed to inflammatory cells, resulting in the production of anti-NMDAR antibodies. Therefore, we suggest that anti-NMDAR encephalitis occurs in women of reproductive ages as a parainfectious disorder, and the presence of ovarian teratoma is a strong predisposing factor for this disease. However, the mechanisms that cause this encephalitis remain unclear, especially in patients without ovarian teratoma, and further studies are needed.

※The authors declare there is no conflict of interest relevant to this article.

References

- 1) Dalmau J, Tüzün E, Wu HY, et al. Paraneoplastic anti-N-methyl-D-aspartate receptor encephalitis associated with ovarian teratoma. *Ann Neurol* 2007;61:25-36.
- 2) Irani SR, Bera K, Waters P, et al. N-methyl-D-aspartate antibody encephalitis: temporal progression of clinical and paraclinical observations in a predominantly non-paraneoplastic disorder of both sexes. *Brain* 2010;133:1655-1667.
- 3) Dalmau J, Lancaster E, Martinez-Hernandez E, et al. Clinical experience and laboratory investigations in patients with anti-NMDAR encephalitis. *Lancet Neurol* 2011;10:63-74.
- 4) Tachibana N, Shirakawa T, Ishii K, et al. Expression of various glutamate receptors including N-methyl-D-aspartate receptor (NMDAR) in an ovarian teratoma removed from a young woman with anti-NMDAR encephalitis. *Intern Med* 2010;49:2167-2173.
- 5) Tüzün E, Zhou L, Baehring JM, et al. Evidence for antibody-mediated pathogenesis in anti-NMDAR encephalitis associated with ovarian teratoma. *Acta Neuropathol* 2009;118:737-743.